



Nota Clínica

Late-onset methylmalonic acidemia and homocysteinemia

Acidemia metilmalónica y homocisteinemia de inicio tardío

Noemi Brox-Torrecilla¹, Loredana Arhip¹, María Miguélez-González¹, Sandra Castellano-Gasch², Ana Contreras-Chicote³,
María Luisa Rodríguez-Ferrero⁴, Marta Luisa Motilla-de la Cámara¹, Clara Serrano-Moreno¹, and Cristina Cuerda Compes¹

¹Nutrition Unit. Hospital General Universitario Gregorio Marañón. Instituto de Investigación Sanitaria Gregorio Marañón. Madrid, Spain. ²Nephrology Department. FMC Dialcentro. Madrid, Spain. ³Neurology Service. Hospital General Universitario Gregorio Marañón. Madrid, Spain. ⁴Nephrology Service. Hospital General Universitario Gregorio Marañón. Madrid, Spain

Abstract

Introduction: cobalamin C (Cbl C) deficiency is the most common defect in intracellular cobalamin metabolism, associated with methylmalonic acidemia and homocystinuria. Its late clinical presentation is heterogeneous and may lead to a diagnostic delay.

Case report: we report the case of a 45-year-old man with a 20-year history of chronic kidney disease and recently diagnosed spastic paraparesis, both of unknown origin. Metabolic studies revealed elevated levels of homocysteine and methylmalonic acid in the blood and urine. A genetic study confirmed cobalamin C deficiency. Treatment with hydroxocobalamin, betaine, carnitine, and folic acid was started. The patient eventually received a kidney transplant.

Discussion: early diagnosis and appropriate treatment improve the clinical evolution of patients with Cbl C deficiency. Determination of homocysteine, organic acids, and other amino acids should be included in the differential diagnosis of patients with nephrological-neurological symptoms without a clear etiology.

Keywords:

Cobalamin C.
Methylmalonic acidemia.
Hyperhomocysteinemia.

Resumen

Introducción: la deficiencia de cobalamina C (Cbl C) es el defecto más común en el metabolismo intracelular de la cobalamina, asociado a acidemia metilmalónica y homocistinuria. Su presentación clínica tardía es heterogénea y puede llevar a un retraso en el diagnóstico.

Caso clínico: presentamos el caso de un varón de 45 años con 20 años de evolución de enfermedad renal crónica y paraparesia espástica de reciente diagnóstico, ambos de origen desconocido. Los estudios metabólicos revelaron niveles elevados de homocisteína y ácido metilmalónico en sangre y orina. El estudio genético confirmó el déficit de cobalamina C. Se inició tratamiento con hidroxocobalamina, betaina, carnitina y ácido fólico. El paciente pudo recibir un trasplante renal.

Discusión: el establecimiento de un diagnóstico precoz y un tratamiento adecuado mejora la evolución clínica de los pacientes con déficit de Cbl C. La determinación de homocisteína, ácidos orgánicos y otros aminoácidos debe incluirse en el diagnóstico diferencial de los pacientes con síntomas nefrológico-neurológicos sin una etiología clara.

Palabras clave:

Cobalamina C.
Acidemia metilmalónica.
Hiperhomocisteinemia.

Received: 25/03/2021 • Accepted: 29/05/2021

The authors followed the CARE guidelines when writing this paper (9).

Funding: this research received no specific grants from funding agencies in the public, commercial, or not-for-profit sectors.

Conflicts of interest: the authors declare no conflicts of interest.

Brox-Torrecilla N, Arhip L, Miguélez-González M, Castellano-Gasch S, Contreras-Chicote A, Rodríguez-Ferrero ML, Motilla-de la Cámara ML, Serrano-Moreno C, Cuerda Compes C. Late-onset methylmalonic acidemia and homocysteinemia. Nutr Hosp 2021;38(4):871-875

DOI: <http://dx.doi.org/10.20960/nh.03623>

Correspondence:

Noemi Brox Torrecilla. Servicio de Endocrinología y Nutrición. Hospital General Universitario Gregorio Marañón. C/ Doctor Esquerdo 46. 28007 Madrid, Spain
e-mail: noemibroxtorrecilla@gmail.com

INTRODUCTION

Cobalamin C (Cbl C) deficiency is the most common inborn error of intracellular cobalamin metabolism. It is caused by mutations in the MMACHC gene located on chromosome 1p34 (1). This mutation results in a decrease in intracellular conversion of vitamin B12 to its two metabolically active forms, adenosylcobalamin (AdoCbl) and methylcobalamin (MeCbl). These are essential coenzymes to methylmalonyl-CoA mutase and methionine synthase (2). A decrease in the activity of these enzymes causes an increase in methylmalonic acid and homocysteine levels in plasma and urine with a decrease in the production of methionine (3). Age at onset differentiates two main forms of presentation: an early-onset form, with a more severe presentation, generally in the first year of life; and a late-onset form, with a milder, more heterogeneous presentation predominantly affecting the central nervous system (4). Clinical suspicion and early diagnosis are fundamental pillars in order to avoid the progression and irreversibility of this multisystemic disease.

CASE REPORT

In this paper we report the case of a 45-year-old man who was referred to our Inherited Metabolic Diseases clinic in 2017 for assessment of a potential metabolic disease due to elevated homocysteine and methylmalonic acid levels in the blood. The patient had chronic kidney disease (CKD) diagnosed in 1995, which was believed to be caused by chronic pyelonephritis; however, a histological study was never performed. He had been on renal replacement therapy through hemodialysis for 3 years. He had no family history of consanguinity or known metabolic diseases. He denied consumption of alcohol and/or drugs.

As associated complications he had presented with repeated episodes of thrombosis in the arteriovenous fistula (up to 4 times), 4 catheter replacements due to thrombosis, and several episodes of tonic-clonic seizures of unclear etiology during hemodialysis. In addition, there was a history of acute encephalopathy with spastic paraparesis in 2010, which he had presented in the context of acute appendicitis and was initially treated with corticosteroid therapy because of a suspected autoimmune etiology. After treatment he experienced a partial improvement in his encephalopathy, but developed a neurogenic bladder and a worsening of lower limb mobility. In 2012 he presented again with an episode of encephalopathy with similar characteristics. The lower limb weakness progressed, completely limiting ambulation, and he was diagnosed with spastic paraparesis of unknown origin. The magnetic resonance images obtained during the neurological study are provided in figure 1.

As a consequence, the patient was studied on multiple occasions by nephrologists and neurologists, who observed elevated levels of homocysteine in the blood, as well as blood folic acid and vitamin B12 levels within the normal range. Despite this, treatment was started with folic acid and vitamin B12 (cyanocobalamin) supplementation.

Subsequently, the neurological condition was studied at the Toledo Paraplegic Hospital, Spain, where very high levels of methylmalonic acid — 117.18 $\mu\text{mol/L}$ (normal range, 0.08-0.56 $\mu\text{mol/L}$) — were detected in the blood. Blood levels of vitamin B12 — 1862 pg/mL (normal range, 220-900 pg/mL) — and folic acid — 20 ng/mL (normal range, 2.5-17 ng/mL) — were also found to be slightly increased. These results prompted physicians to refer the patient to our Inherited Metabolic Diseases clinic.

Since the patient presented with anuria due to dialysis, and a urine sample could therefore not be obtained, a larger meta-

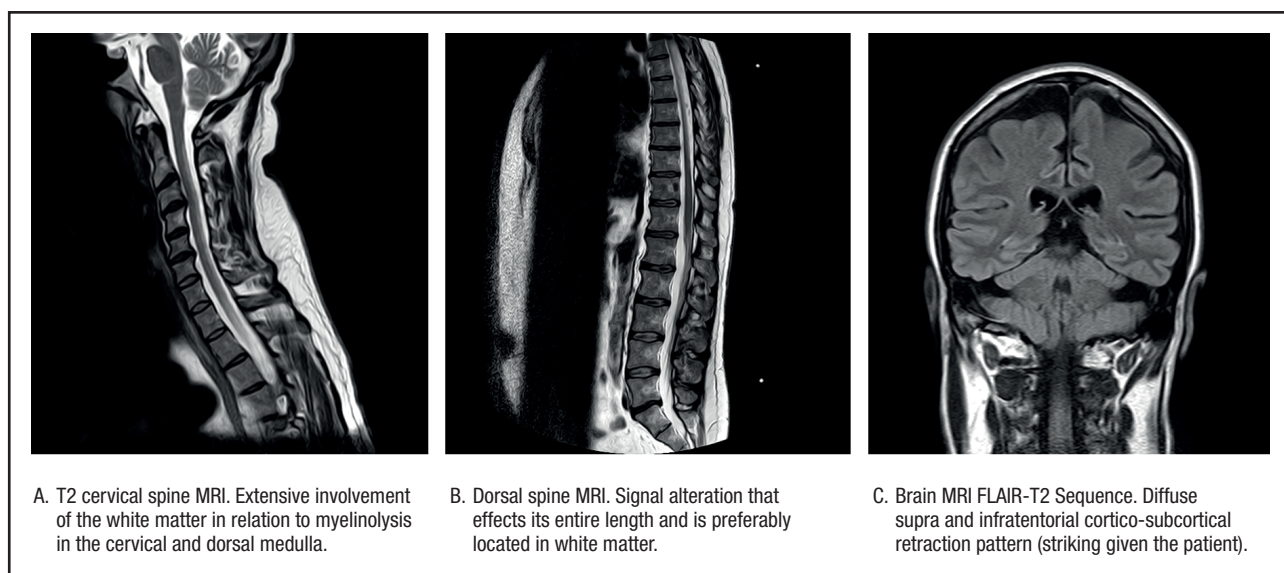


Figure 1.

Magnetic resonance images obtained during the neurological study.

bolic study was decided to be carried out using blood chemistry. The levels of methylmalonic acid in the blood were 2.32 $\mu\text{mol/L}$ and those of homocysteine were 45.4 $\mu\text{mol/L}$. The study was completed with an assessment of pristanic acid, phytanic acid, and very long-chain fatty acids in the serum, which came back normal. A genetic study confirmed methylmalonic acidemia with homocystinuria due to Cbl C deficiency related to mutations in the MMACHC gene. Two variants previously described as pathogenic (p.Ser146Argfs*35 and p.Arg161Gln) were identified in the MMACHC gene. Therefore, a genetic study of the parents was recommended to confirm the presence of variants in different alleles.

Treatment was started with hydroxocobalamin at a dose of 1 mg/day IM initially, which was subsequently down-titrated to twice a week as maintenance dose. Additional treatment consisted of 3 g every 8 hours of betaine, 20–25 mg/kg of carnitine, and 5 mg of folic acid, daily. After starting treatment the patient experienced a partial improvement of his neurological manifestations. He received a kidney transplant in June 2018 once the etiology of CKD was known.

During the last visit in July 2020 the patient showed good metabolic control with methylmalonic acid levels within the normal range, and slightly elevated homocysteine levels. The evolution of homocysteine and methylmalonic acid levels is shown in figures 2, 3 and 4. The patient reported that he was well, maintaining an

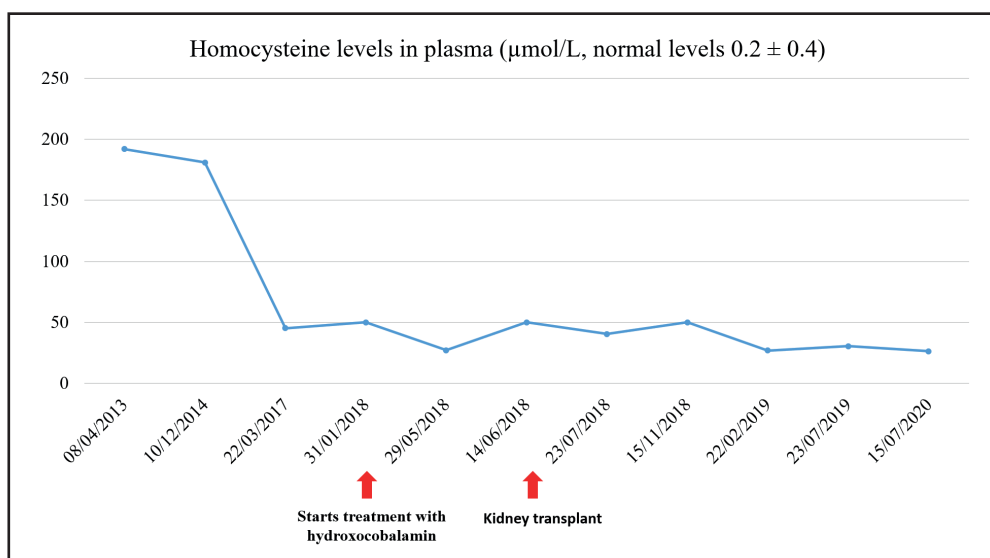


Figure 2.

Levels of homocysteine in plasma.

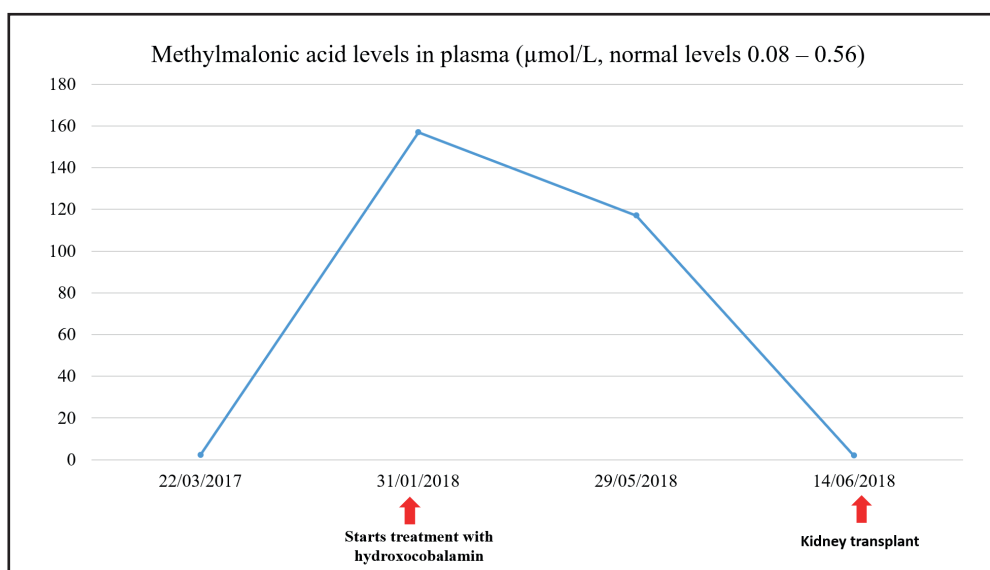


Figure 3.

Levels of methylmalonic acid in plasma.

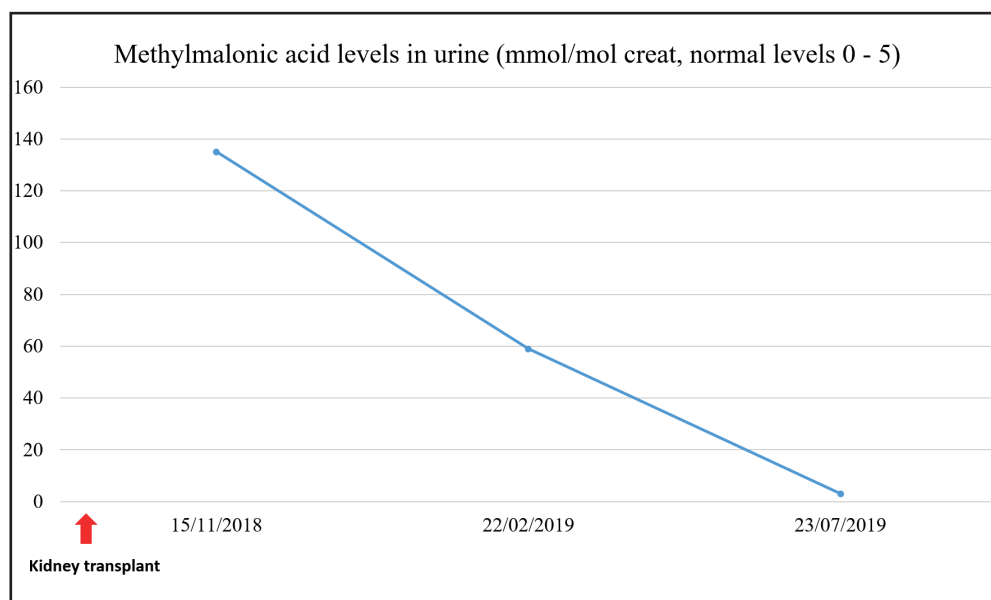


Figure 4.

Levels of methylmalonic acid in urine.

active life, going to physical rehabilitation and a gym on a regular basis. He needs a wheelchair to move around, although he has regained some mobility in the lower limbs. He is the carrier of a permanent urinary catheter but renal function is preserved and stable.

DISCUSSION

In this paper we report the case of a patient with a rare metabolic disease that because of being associated with late onset, heterogeneity in clinical presentation, and absence of clinical suspicion represents a diagnostic challenge. Although this is a rare disease, in 2007 there were about 250 cases published in the literature (4). However, when focusing exclusively on patients with late presentation, in 2014 Huemer et al. published a review of the literature in which they included 61 cases (5). Subsequently, in 2019 Wang et al. reported 16 new cases (2).

Despite the fact that late presentation represents a less severe form, and has a more favorable prognosis, than early presentation, the diagnosis is usually delayed due to an absence of clinical suspicion. Huemer et al. described that diagnosis may be delayed for more than 20 years, as was the case with our patient (5).

Regarding the clinical symptoms, myelopathy and dementia are the most frequent and invalidating characteristics that these patients face. The study by Wang et al. revealed that up to 100 % of their patients presented with alterations in the pyramidal tract on physical examination (2). Their pathophysiology appears to lie in the demyelination caused by low levels of adenosylcobalamin, in methionine deficiency, and in the neurotoxicity caused by high levels of methylmalonic acid (5).

Although representing a rare clinical feature of this condition (5), kidney disease was the initial manifestation in our patient. The delayed diagnosis probably influenced the progressive deterioration of renal function, and the need for renal replacement therapy. Furthermore, the lack of an accurate diagnosis in this regard meant that the patient was not initially a candidate for kidney transplantation. Finally, after reaching a diagnosis and prescribing an optimal treatment the patient was able to receive a kidney transplant in 2018, and currently has preserved kidney function.

Associated with this entire clinical spectrum is a state of hypercoagulability caused by hyperhomocysteinemia, which manifests as an increased incidence of thrombosis (6). Our patient had suffered from a total of 4 fistular thromboses and 4 catheter thromboses. In this case, elevated levels of homocysteine in the blood were accounted for by renal failure although, usually, when it comes to renal failure, homocysteine levels are not as high as in the case reported herein (7).

It should be noted that, in this pathology, the affection of vitamin B12 metabolism is intracellular, and therefore plasma levels of vitamin B12 remain normal, which renders the diagnosis extremely difficult. In fact, in our patient, they had been measured on several occasions and the results were always normal.

Therefore, within the initial study of myelopathies, CKD, and thrombophilias of unknown origin it is necessary not only to measure vitamin B12 and folic acid levels in the blood, but also homocysteine, organic acids, and other amino acids both in the urine and plasma (8).

Finally, we believe that the publication of these clinical case reports (including ours) provides scientific knowledge on infrequent causes of nephrological and neurological disorders, in which an accurate diagnosis and early treatment are a priority to

improve the progressive and disabling course of disease, with the potential to even reverse it when in early stages (8).

CONCLUSION

The establishment of appropriate treatment considerably improves the clinical outcome of patients with Cbl C deficiency. A measurement of homocysteine, organic acid, and other amino acid levels should be included in the differential diagnosis of patients with nephrological-neurological symptoms of unclear etiology.

REFERENCES

1. Lerner-Ellis JP, Grading AB, Watkins D, Tirone JC, Villeneuve A, Dobson CM, et al. Mutation and biochemical analysis of patients belonging to the cblB complementation class of vitamin B12-dependent methylmalonic aciduria. *Mol Genet Metab* 2006;87(3):219-25. DOI: 10.1016/j.ymgme.2005.11.011
2. Wang X, Yang Y, Li X, Li C, Wang C. Distinct clinical, neuroimaging and genetic profiles of late-onset cobalamin C defects (cblC): a report of 16 Chinese cases. *Orphanet J Rare Dis* 2019;14(1):109. DOI: 10.1186/s13023-019-1058-9
3. Backe PH, Ytre-Arne M, Røhr ÅK, Brodtkorb E, Fowler B, Rootwelt H, et al. Novel deletion mutation identified in a patient with late-onset combined methylmalonic acidemia and homocystinuria, CBLC type. In: *JIMD Reports* 2013;11:79-85. DOI: 10.1007/8904_2013_225
4. Ben-Omran TI, Wong H, Blaser S, Feigenbaum A. Late-onset cobalamin-C disorder: A challenging diagnosis. *Am J Med Genet Part A* 2007;143(9):979-84. DOI: 10.1002/ajmg.a.31671
5. Huemer M, Scholl-Bürgi S, Hadaya K, Kern I, Beer R, Seppi K, et al. Three new cases of late-onset cblC defect and review of the literature illustrating when to consider inborn errors of metabolism beyond infancy. *Orphanet J Rare Dis* 2014;9:161. DOI: 10.1186/s13023-014-0161-1
6. Stamler JS, Osborne JA, Jaraki O, Rabbani LE, Mullins M, Singel D, et al. Adverse vascular effects of homocysteine are modulated by endothelium-derived relaxing factor and related oxides of nitrogen. *J Clin Invest* 1993;91(1):308-18. DOI: 10.1172/JCI116187
7. Jamison RL, Hartigan P, Kaufman JS, Goldfarb DS, Warren SR, Guarino PD, et al. Effect of homocysteine lowering on mortality and vascular disease in advanced chronic kidney disease and end-stage renal disease: A randomized controlled trial. *J Am Med Assoc* 2007;298(10):1163-70. DOI: 10.1001/jama.298.10.1163
8. Tsai ACH, Morel CF, Scharer G, Yang M, Lerner-Ellis JP, Rosenblatt DS, et al. Late-onset combined homocystinuria and methylmalonic aciduria (cblC) and neuropsychiatric disturbance. *Am J Med Genet Part A* 2007;143(20):2430-4. DOI: 10.1002/ajmg.a.31932
9. Gagnier JJ, Kienle G, Altman DG, Moher D, Sox H, Riley D. The CARE guidelines: Consensus-based clinical case reporting guideline development. *Forsch Komplementarmed* 2013;20(5):385-6. DOI: 10.7453/gahmj.2013.008