



Original / *Nutrición parenteral*

Successful management of chylous ascites with total parenteral nutrition and octreotide in children

Chao Yang, Jun Zhang, Shan Wang, Chang-chun LI, Xiang-ru Kong and Zhenzhen Zhao

Department of Pediatric surgical oncology. Children's Hospital of Chongqing Medical University. Chongqing. China

Abstract

Purpose: To evaluate the effects of total parenteral nutrition and octreotide on pediatric patients with chylous ascites post-operative.

Methods: Four patients were diagnosed with chylous ascites from nov 2009 to nov 2012. Total parenteral nutrition and octreotide was administered to 2 patients, while the other two only received fasting and total parenteral nutrition. All patients had persistent peritoneal drainage, with the quantity and quality of drainage fluid observed daily.

Results: Two patients who received somatostatin therapy completely recovered within 7d without any recurrence while on a normal diet. The other two patients who only received fasting and total parenteral nutrition was cured 24-30d after therapy.

Conclusion: Total parenteral nutrition along with octreotide can relieve the symptoms and close the chyle leakage in patients with chylous ascites rapidly. It seems to be an effective therapy available for the treatment of chylous ascites.

(*Nutr Hosp.* 2013;28:2124-2127)

DOI:10.3305/nh.2013.28.6.6480

Key words: *Chylous ascites. Total parenteral nutrition. Octreotide. Pediatric.*

ÉXITO DE LA GESTIÓN DE LA ASCITIS CON NUTRICIÓN PARENTERAL TOTAL Y OCTREÓTIDA EN NIÑOS

Resumen

Propósito: Evaluar los efectos de la nutrición parenteral total y el octreótido en pacientes pediátricos con ascitis quilosa posoperatoria.

Métodos: Se diagnosticó a cuatro pacientes de ascitis quilosa entre noviembre de 2009 y noviembre de 2012. Se administraron nutrición parenteral total y octreótido a dos 2 parientes, mientras que los otros dos sólo recibieron ayuno y nutrición parenteral total. Todos los pacientes tuvieron drenaje peritoneal persistente, observándose la cantidad y calidad del líquido de drenaje a diario.

Resultados: Los dos pacientes que recibieron el tratamiento con somatostatina se recuperaron por completo en 7 días, sin recurrencia cuando instauraron una dieta normal. Los otros dos pacientes que sólo realizaron ayuno y nutrición parenteral total se curaron después de 24-30 días de tratamiento.

Conclusión: La nutrición parenteral total junto con el octreótido pueden aliviar rápidamente los síntomas y cerrar la fuga de quilo en pacientes con ascitis quilosa. Parece ser un tratamiento eficaz para la ascitis quilosa.

(*Nutr Hosp.* 2013;28:2124-2127)

DOI:10.3305/nh.2013.28.6.6480

Palabras clave: *Ascitis quilosa. Nutrición parenteral total. Octreótido. Pediátrico.*

Introduction

Chylous ascites is the extravasation of milky chyle rich in triglycerides into the peritoneal cavity. Postoperative chylous ascites is not so rare in the pediatric population. They more commonly occur after retroperitoneal operations¹. Chylous ascites may lead

to additional morbidity in pediatric patients. Conservative treatment of chylous ascites, recommended in most patients, involves paracentesis, a medium chain triglyceride (MCT) based diet, total parenteral nutrition (TPN). Although chylous leak can be corrected by surgical interventions, surgery is invasive and requires expertise and is associated with significant mortality². Therefore, a pharmacologic agent that closed of the leak seemed to be very valuable in the treatment of chylous effusion. The use of somatostatin and its analogs (octreotide) has recently been introduced into the management of iatrogenic chylothorax and chyloperitoneum in children^{3,4}, however this treatment was still with little experience in world literature, especially in pediatric population. Here we report on our

Correspondence: Shan Wang.
136 Zhongshan 2nd Road.
Yuzhong Distric. Chongqing.
400014 China.
E-mail: 50384634@qq.com

Recibido: 16-I-2013.
1.^a Revisión: 6-II-2013.
Aceptado: 8-II-2013.

successful use of persistent peritoneal drainage, TPN as well as octreotide in treatment of 4 cases of chylous ascites.

Materials and methods

Four patients with chylous ascites were included in this study from November 2009 to Nov 2012. All patients developed chylous ascites after surgery. There was no congenital chylous ascites. Patient 1 was a 4 month infant with retroperitoneal teratoma, and developed chylous ascites 1 week after tumor resection. Two patients (patient 2 and 4) with retroperitoneal neuroblastoma were diagnosed as chylous ascites 1 month and 2 weeks after surgery respectively. Patient 2 was operated in another hospital, and administrated to our hospital due to abdominal distention one month after surgery. Patient 3 was a celiac Burkitt lymphoma with ileocecus mesentery lymph node enlargement, and chylous ascites was observed 10 day after ileocecus mesentery lymphadenectomy. The diagnosis was confirmed by analyzing the ascites fluid obtained through peritoneal drainage. Table I shows the clinical features and laboratory findings of ascites samples from 4 patients.

As soon as the diagnosis was confirmed, every patient was put in fasting state and received fluid therapy to correct the disturbance of water, electrolytes and acid-base. A single lumen central venous catheter was inserted into the peritoneal cavity for continuous drainage in 1 patients (patient 2), while peritoneal cavity drainage tubes inserted during the operation were reserved in the other 3 patients. The quality and quantity of drainage fluid were monitored daily. Then TPN as administered to patients at gradually increasing dose. During TPN administration, liver function and blood fat were monitored every week for all patients. Patient 1 and 3 received continuous intravenous infu-

sion of the octreotide (Sandostatin, Novartis Pharma AG), at an initial dose of 1.0 mcg/kg/h, with an increase of 1.0 mcg/kg/hr/day until a maximum dose of 2.0 mcg/kg/h. Necessary supportive treatments, such as albumin, diuretics and antibiotics were given to the patients individually during the therapy. Finally, any adverse effects that could be attributed to octreotide were also noted.

Results

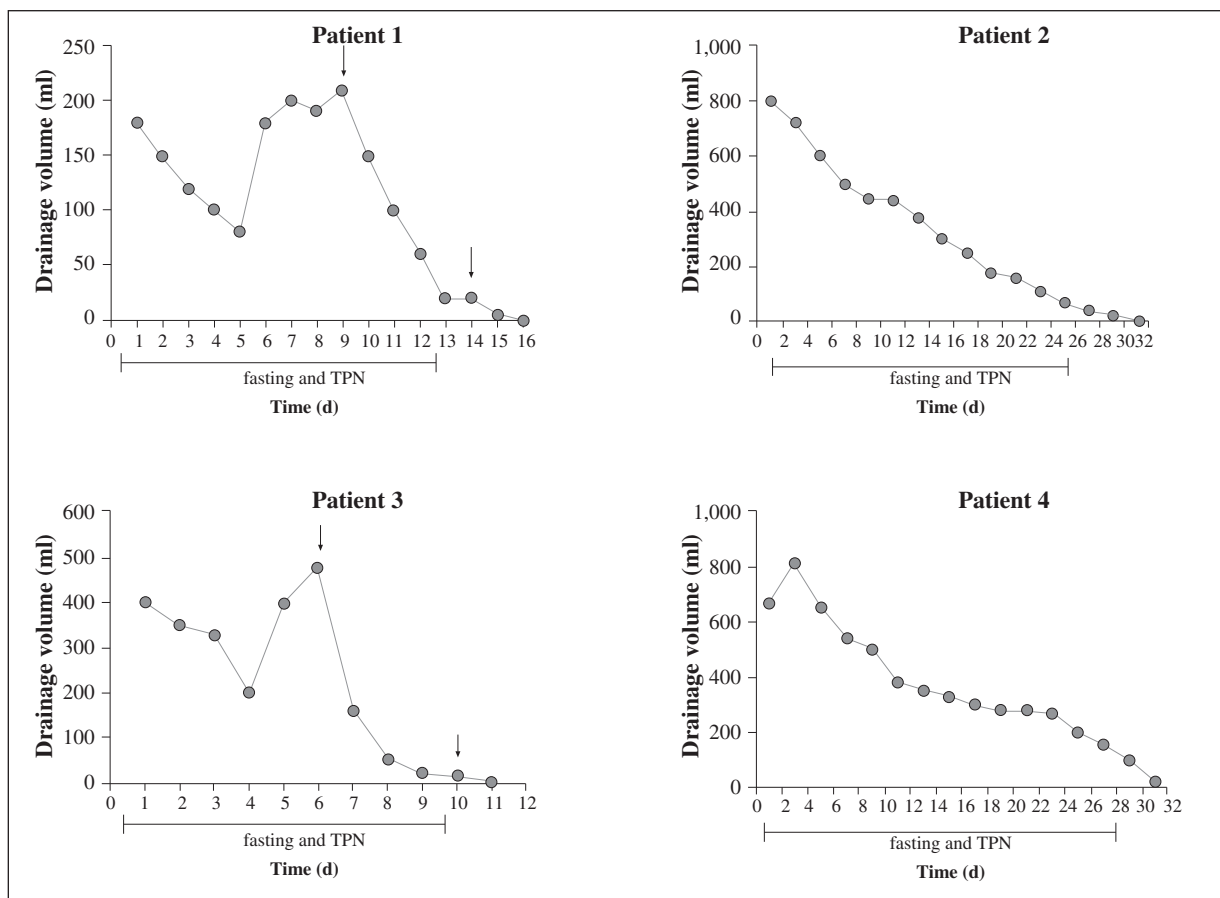
Figure 1 to 4 shows the change of drainage volume, the duration of TPN and octreotide therapy of 4 patients. Of the two patients with chylous ascites who received octreotide therapy, peritoneal drainage volume were decreased dramatic after octreotide administration, and completely recovery within 7 d, while patients who only received TPN was cured 24-30 d after therapy. Once the peritoneal drainage was zero or was proved non-chylous ascites, TPN and octreotide dose would diminish gradually along with the recovery of oral low fat diet. CT follow-up examinations did not reveal the presence of ascitic fluid. Follow-up study found no recurrence in these patients while on normal diet. No complications related TPN were observed during TPN administration. And no side effect was observed at follow-up.

Discussion

The main etiology of chylous ascites in children is congenital. Other causes of chylous ascites in children are either idiopathic or obstructive lesions caused by malrotation, intussusception, incarcerated hernia, lymphangioma, blunt trauma, liver disease, and tuberculosis⁵. However, chylous ascites is considered an uncommon complication after abdominal surgery. Radiologic

Table I
Clinical features and laboratory findings for 4 patients with chylous ascites

Patient	Age	Medical condition	Laboratory findings of ascites			
			Qualitative analysis of chyle	Albumin (g/L)	Cholesterol (mmol/L)	Triglyceride (mmol/L)
1	4 month	1 week after retroperitoneal teratoma resection	positive	31	1.8	4.2
2	2y4m	1 month after retroperitoneal neuroblastoma resection	positive	30.2	1.2	3.6
3	3y6y	10 day after ileocecus mesentery lymphadenectomy for celiac lymphoma	positive	33	1.77	4.23
4	3y8m	2 weeks after retroperitoneal neuroblastoma resection	positive	31.5	0.9	2.3



Figs. 1-4.—Change of drainage volume and the duration of TPN and octreotide therapy in 4 patients. ↓ The beginning and the end of TPN.

imaging (CT or MRI/MRA) may not be sensitive in identifying the precise location of lymphatic channel injury after surgery, although chyle has less attenuation on CT or MR studies than blood, distinguishing it from acute hemorrhage⁶. The loss of lymphatic fluid causes hypoalbuminemia, hydroelectrolyte alterations, coagulation and immunodeficiency with important involvement of clinical condition of the child and increased morbidity and mortality⁷. There are conservative and surgical treatments for chylous ascites, and the latter is usually indicated after failure of conservative treatment after two to three weeks⁸. However, such procedure is limited by anatomic variations of the duct location, as well as difficulty to identify the drainage site⁹.

The management of chylous ascites after surgery comprises a spectrum of interventions, from dietary management to exploratory laparotomy. Fasting, together with TPN, can decrease the lymph flow in thoracic duct dramatically from 220 mL/(kg·h) to 1 mL/(kg·h)¹⁰. Furthermore, TPN restores nutritional deficits and balances metabolic impairments imposed by chylous ascites and repeat sessions of paracentesis. So fasting and TPN are essential in nonoperative management of chylous ascites¹¹. Surgical ligation of the chylous fistula is recommended when conservative

treatment fails. However, conservative treatment may need much more time to recover, in Leibovitch's report, routine conservative treatment, using TPN only or combined with an MCT diet, needed 2 to 6 wk to cure 60% to 100% of cases¹. In our study, patient 2 and 4 who only received fasting and TPN recovered completely between 24-30 d.

Octreotide, a synthetic, long-acting somatostatin analogue, has been suggested as a therapeutic agent in the management of several clinical disorders. By inhibiting the secretion of some pituitary and gastrointestinal hormones, octreotide can increase splanchnic arteriolar resistance, reduce gastrointestinal flow and, consequently, the lymph flow¹². However, the clinical experience with octreotide is limited in pediatric patients. A somatostatin analog was first used for postoperative chylous ascites in a pediatric patient in 2001, as reported by Lam et al⁴. Reports of successful management with octreotide for pediatric chylothorax and chylous ascites were increasing in recent ten years^{9,13-17}, the effect were promising which reducing recovering time and the potential need for surgical intervention and without obviously side effects⁸, however, there were few reports of octreotide treatment for chylous ascites post-operation. In our series, all 4 patients presented with chylous

ascites after surgery, 2 out of 4 patients were successfully treated with octreotide. The output of drainage tubes were persistent, even increased, in two patients although they were fasting for 6-10 days but resolved immediately after the use of octreotide. Given the observed rapid resolution of chylous effusion with the octreotide administration, it appears that octreotide infusion rather than natural healing was responsible for the closure of chyle leakage, though the mechanism still needs further investigation. When comparing the two patients who only received fasting and TPN, octreotide therapy with TPN obviously shortened the curative time, decreased the treatment cost and no significant side effect was observed.

Side effects of octreotide relate to reduced sperm motility and intestinal secretion: hypertension, malabsorption, nausea, flatulence, hepatic dysfunction and hyperglycemia¹⁸. However, there are few side effects observed in literature reports, as well as our follow-up of patients using octreotide. Because octreotide interferes with blood glucose regulation, close monitoring of blood glucose and gradual tapering of octreotide is recommended.

Oral or enteral MCT-rich diet accompanying the adequate draining was recommended in some study¹⁹, MCT-rich diet not only provides adequate nutrition, but also decreases the lymph leak in order to support healing. However, if lymphatic effusion does not decrease, oral or enteral feeding should be stopped and TPN should be initiated. In our series, all patients put in fasting state and received TPN until the drainage was zero or was proved non-chylous ascites. All patients began with low-fat or no-fat MCT-rich diets and transitioned to normal diet gradually. No recurrence was observed in all patients.

Conclusion

The results found in our study are encouraging with respect to drug safety, and favorable outcome in the treatment of chylous ascites. Although lack of prospective randomized study, on the basis of previous reports and our experience, we suggest that TPN with octreotide should be considered as a possible prior therapeutic option in managing pediatric post-operative chylous ascites. Further studies of multicenter clinical trials involving more patients to compare the effectiveness and cost between this therapy and the others are suggested.

References

1. Leibovitch I, Mor Y, Golomb J, Ramon J. The diagnosis and management of postoperative chylous ascites. *J Urol* 2002;167 (2 Pt 1): 449-57.
2. Browse NL, Wilson NM, Russo F, al-Hassan H, Allen DR. Aetiology and treatment of chylous ascites. *Br J Surg* 1992; 79 (11): 1145-50.
3. Pratap U, Slavik Z, Ofue VD, Onuzo O, Franklin RC. Octreotide to treat postoperative chylothorax after cardiac operations in children. *Ann Thorac Surg* 2001; 72 (5): 1740-2.
4. Lam JC, Aters S, Tobias JD. Initial experience with octreotide in the pediatric population. *Am J Ther* 2001; 8 (6): 409-15.
5. Unger SW, Chandler JG. Chylous ascites in infants and children. *Surgery* 1983; 93 (3): 455-61.
6. Hibbeln JF, Wehmueller MD, Wilbur AC. Chylous ascites: CT and ultrasound appearance. *Abdom Imaging* 1995; 20 (2): 138-40.
7. Sahin Y, Aydin D. Congenital chylothorax treated with octreotide. *Indian J Pediatr* 2005; 72 (10): 885-8.
8. Yildirim SV, Kervancio lu M, Sarita B, Varan B, Mercan S, Tokel K. Octreotide infusion for the treatment of chylothorax in pediatric cardiac intensive care unit. *Anadolu Kardiyol Derg* 2005; 5 (4): 317-8.
9. Pessotti CF, Jatene IB, Buononato PE, Elias PF, Pinto AC, Kok MF. Use of octreotide in the treatment of chylothorax and chyloperitoneum. *Arq Bras Cardiol* 2011; 97 (2): e33-6.
10. Aalami OO, Allen DB, Organ CH Jr. Chylous ascites: a collective review. *Surgery* 2000; 128 (5): 761-78.
11. Huang Q, Jiang ZW, Jiang J, Li N, Li JS. Chylous ascites: treated with total parenteral nutrition and somatostatin. *World J Gastroenterol* 2004; 10 (17): 2588-91.
12. Cheung Y, Leung MP, Yip M. Octreotide for treatment of post-operative chylothorax. *J Pediatr* 2001; 139 (1): 157-9.
13. Huang Y, Zhuang S, Li Y, Liu M, Chen H, Du M. Successful management of congenital chylous ascites in a premature infant using somatostatin analogue. *Indian J Pediatr* 2011; 78 (3): 345-7.
14. Huang CC, Tsai MS, Lai HS. Chylous ascites after excision of a choledochal cyst in a child. *J Pediatr Surg* 2009; 44 (5): e5-7.
15. Baran M, Cakir M, Yükksekaya HA, Arikian C, Aydin U, Aydogdu S, et al. Chylous ascites after living related liver transplantation treated with somatostatin analog and parenteral nutrition. *Transplant Proc* 2008; 40 (1): 320-1.
16. Andreou A, Papouli M, Papavasiliou V, Badouraki M. Postoperative chylous ascites in a neonate treated successfully with octreotide: bile sludge and cholestasis. *Am J Perinatol* 2005; 22 (8): 401-4.
17. Park KT, Adikibi B, MacKinlay GA, Gillett PM, Sylvester KG, Kerner JA. Chylous ascites after laparoscopic Nissen fundoplication. *Dig Dis Sci* 2012; 57 (1): 28-31.
18. Lim KA, Kim SH, Huh J, Kang IS, Lee HJ, Jun TG et al. Somatostatin for postoperative chylothorax after surgery for children with congenital heart disease. *J Korean Med Sci* 2005; 20 (6): 947-51.
19. Densupsoontorn NS, Jirapinyo P, Wongarn R, Thamonsiri N, Nana A, Laohaprasitiporn D, et al. Management of chylothorax and chylopericardium in pediatric patients: experiences at Siriraj Hospital, Bangkok. *Asia Pac J Clin Nutr* 2005; 14 (2): 182-7.