



## Revisión

# Revision surgery for one anastomosis gastric bypass with anti-reflux mechanism: a new surgical procedure using only not previously operated intestine

Manuel Garcíacaballero<sup>1</sup>, Alexander Reyes-Ortiz<sup>1,2,3</sup>, Manuel Martínez-Moreno<sup>1</sup>, Alfredo Mínguez-Mañanes<sup>1</sup>, José Antonio Toval-Mata<sup>1</sup>, Diego Osorio-Fernández<sup>1</sup> and José María Mata-Martín<sup>1</sup>

<sup>1</sup>Dept. of Surgery University Malaga, Spain. <sup>2</sup>Autonomous University of the State of México (UAEMex). <sup>3</sup>U.M.F. 229, Del. 16. Mexican Social Security Institute. México.

## Abstract

**Introduction:** Obesity is now an epidemic in industrialized countries with high prevalence (U.S. with 67%, Europa from 40% to 50%). This had led to the development of many bariatric procedures. Nevertheless, the primary surgery could fails due to several conditions. There is no standard re-operative procedure of revision for primary bariatric failure. Re-operate in the place of the primary surgery imply high rate of risks. We have developed a new procedure for revision surgery working only on not previously operated tissue.

**Methods:** We measure the common channel from gastro-jejunal anastomosis until the ileocecal valve. Depending on the measure, we decide the length of intestine to be excluded (biliopancreatic limb and common channel). We interrupt the afferent loop before gastro-jejunostomy and the efferent loop 20 cm below the gastro-jejunostomy. For restoring the gastro-intestinal transit, we anastomose the upper part of the afferent and efferent loop side-to-side and the efferent loop segment to the upper part of the new common channel.

**Discussion:** There is no standard procedure for revision of primary surgery. Even, the gold standard surgery Roux-en-Y gastric bypass is one of the most failed procedure ( $\leq 35\%$ ). We have developed the revision for One Anastomosis Gastric Bypass (BAGUA) working always in healthy tissue not previously used.

**Conclusions:** A few number of patients with tailored BAGUA for morbid obesity will require a surgical rescue procedure due to excess or insufficient weight loss or weight regain. This new procedure has been proven to be easy and safe, avoiding the surgical difficulties of the classical revision through the scar tissue.

(Nutr Hosp. 2014;30:1232-1236)

DOI:10.3305/nh.2014.30.6.8121

Key words: One Anastomosis Gastric Bypass. Total length small intestinal. Revision surgery. Insufficient weight loss and Weight re-gain.

**Correspondence:** Manuel Garcíacaballero.  
Full Professor of Surgery. University of Malaga. Medical Faculty.  
29080 Malaga. Spain.  
E-mail: gcaballe@uma.es

Recibido: 24-IX-2014.

Aceptado: 23-X-2014.

## CIRUGÍA DE REVISIÓN DE BYPASS GÁSTRICO DE UNA ANASTOMOSIS CON MECANISMO ANTI-REFLUJO: UN NUEVO PROCEDIMIENTO QUIRÚRGICO UTILIZANDO SOLO INTESTINO NO OPERADO ANTERIORMENTE

## Resumen

**Introducción:** La obesidad es ahora una epidemia en los países industrializados con una alta prevalencia (Estados Unidos con el 67%, Europa desde el 40% al 50%). Esto ha llevado al desarrollo de muchos de los procedimientos bariátricos. Sin embargo, la cirugía primaria puede fallar debido a diversas condiciones. No existe un procedimiento quirúrgico standard para realizar revisión para la cirugía bariátrica que ha fallado. Re-operar en el lugar de la cirugía primaria implicar una alta tasa de riesgos. Nosotros hemos desarrollado un nuevo procedimiento para la cirugía de revisión trabajando únicamente en el tejido no operado previamente.

**Métodos:** Nosotros medimos el canal común desde de la anastomosis gastro-yeyunal hasta la válvula ileocecal. Dependiendo de la medición, decidimos la longitud del intestino para ser excluido (asa biliopancreática y canal común). Interrumpimos el asa aferente antes gastro-yeyunostomía y el asa eferente a 20 cm por debajo de la gastro-yeyunostomía. Para restaurar el tránsito gastro-intestinal, anastomosamos la parte superior del asa aferente y eferente en forma latero-lateral, y el segmento del asa eferente a la parte superior del nuevo canal común.

**Discusión:** No existe un procedimiento estándar para la revisión de la cirugía primaria. Incluso, la cirugía Gold standard el bypass gástrico Roux-en-Y, es uno de los procedimientos con más fracasos ( $\leq 35\%$ ). Hemos desarrollado la revisión del Bypass Gástrico de Una Anastomosis (BAGUA) trabajando siempre en tejido sano no utilizado previamente.

**Conclusiones:** Un escaso número de pacientes con BAGUA a medida para obesidad mórbida requerirá un procedimiento de rescate quirúrgico debido a exceso de peso o pérdida de peso insuficiente, o la re-ganancia del peso. Este nuevo procedimiento ha demostrado ser fácil y seguro, evitando las dificultades quirúrgicas de la revisión clásica a través del tejido cicatrizado.

(Nutr Hosp. 2014;30:1232-1236)

DOI:10.3305/nh.2014.30.6.8121

Palabras claves: Bypass Gástrico de una anastomosis. Longitud total del intestino delgado. Cirugía de revisión. Insuficiente pérdida de peso y Re-ganancia de peso.

## Introduction

Obesity is now epidemic in industrialized countries. The prevalence of obesity is high in countries such as the U.S. where 67% of the population is overweight or obese. Prevalence in European countries ranges from 40% to 50%<sup>1</sup>. This high prevalence of morbid obesity worldwide has resulted in the development of many bariatric surgical procedures, which have proven to be more effective for sustained long-term weight loss than nonsurgical treatment. Nevertheless, since the early 1980s, it is known that some patients may require a second surgery due to inadequate weight loss or weight re-gain<sup>2</sup>, excess weight loss<sup>3</sup> or other reasons.

The great amount of bariatric primary surgeries for treating obesity, has led to an increasing number of reoperations for failed bariatric procedures. The reasons and types of these operations are varied in nature<sup>4</sup>. It has been demonstrated that weight regain could be due to lack of control over food intake that can produce addictive behaviors to some kind of food, lack of self-monitoring or fewer postoperative follow-up visits<sup>5,6</sup>.

Revision of bariatric surgery is a complex and growing surgical field<sup>3</sup>. There is no standard re-operative procedure for the failure of primary bariatric surgery<sup>7</sup>. The vast majority of bariatric surgeons perform corrective surgery based on their own experience<sup>2,7,8</sup>. Reoperations imply work on scar tissues, with strong adhesences, without defined dissection plane, highly vascularized and, hence, of higher risk than primary surgery. In spite of that, the expected weight loss results are lower than in primary surgery although is a good solution for the comorbidities<sup>9,10,11</sup>.

So, reoperations involve a complex decision process that includes assessing the current state of the cases that has failed and make the identification of a safe alternative<sup>2,12</sup>. Bariatric surgeons must analyze the indication of revision surgery on a case-by-case basis, and choosing an easy and safe revision procedure<sup>2,13</sup>. Many revision surgical alternatives have been described. Most of them imply undo the primary surgery and make it back to. Another alternative is the use of rings or bands for inducing restriction of food intake. Nevertheless, both alternatives need to be performed on scar tissue. An ideal solution will be to have the opportunity of performing revision surgery on healthy tissue as we do in primary surgery. That is the alternative we have found and use for revision in One Anastomosis Gastric Bypass (BAGUA).

## Methods

### Preoperative management

In all selected patients to re-operate, a preoperative study was conducted following the indications of the

Clinical Practice Guideline (CPG) of the European Association for Endoscopic Surgery (EAES)<sup>14</sup>.

Before surgery, all patients eat only liquid diet depending of preoperative BMI during 5 (BMI <34) to 7 days (BMI >35), received antibiotic and antithrombotic prophylaxis.

### Detailed description of the new surgical technique

In surgery, the surgeon stands between the patient's legs. The procedure begins introducing a Veress needle at the left subcostal space in order to create the pneumo-peritoneum. We use four trocars introduced in the same points as in primary surgery (Tailored One Anastomosis Gastric Bypass) but approximately 10 cm down (see figure 1). We put the first trocar of 10 mm in the middle line of the abdomen for the camera. The second trocar of 12 mm is positioned around 10 cm to the right side of the first trocar from the position of the surgeon. The third trocar of 12 mm is placed around 10 cm to the left side of the first one trocar at the same level. The fourth trocar of 5 mm is put with internal vision control with the camera, in the left flank at the lower edge of the subcostal border, and it is used to separate the stomach and visceral fat, and others operation maneuvers with the intestinal loop. It is not necessary to retract the liver because we work below the gastrojejunal anastomosis.

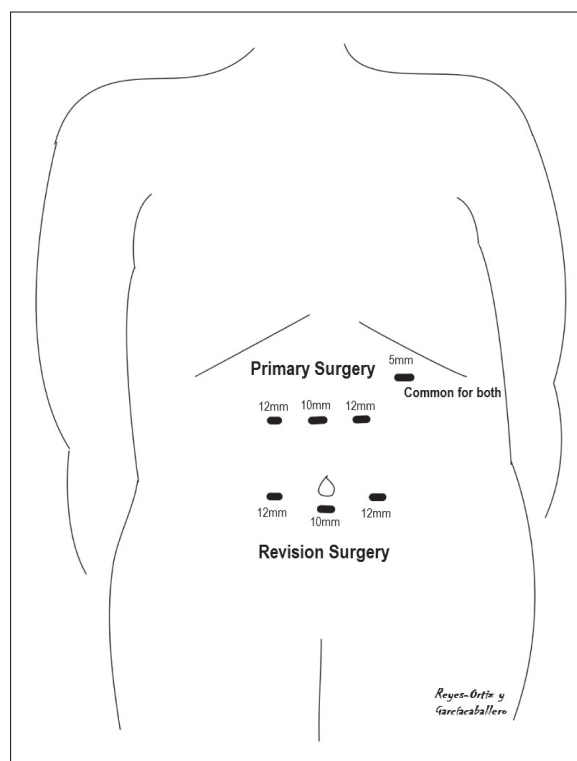


Fig. 1.—Trocarr site in primary (upper lines: 10 mm in centre and 12 mm at both side) and revision surgery (lower lines). The 5 mm trocar in the left subcostal space is the same in both cases.

We start the surgical procedure measuring the length of the common channel from gastro-jejunal anastomosis to the ileocecal valve. Depending on it, we decide the length of intestine to be excluded. As can be seen in figure 2, if we found a total small intestine length of 6 m and a biliopancreatic limb of 2 m with 4 m of common channel from the primary surgery, we excluded another 2 m. Then, after the revision surgery, the patient will have 4 m of intestine excluded (new biliopancreatic limb length) and only 2 m of common channel. Six meters is the more frequent total small intestine length in human beings. The proportion between excluded intestine and common channel described above is based in the large experience when we used a standard procedure that excluded 2 m small intestine distal to the Treitz ligament for all patients. In case we measure a total small intestine length shorter or longer than 6 m, we calculate the length of excluded intestine and common channel proportionally to what we do when the total small intestine length is 6 m.

Once decided the new measures of biliopancreatic limb and common channel, we proceed interrupting the continuity of the afferent loop just before gas-

tro-jejunosomy and the efferent loop 20 cm below the gastro-jejunosomy in both cases using stapler of 60 mm blue cartridge (EndoGhia 60 mm, 3.5 mm, Covidien®). Then we anastomose the upper part of the afferent and efferent loop side-to-side using a 45 mm stapler blue cartridge in order to restore the intestinal transit (Fig. 2B). Finally, we performed a second side-to-side anastomosis between the 20 cm of the efferent loop segment after primary gastro-jejunal anastomosis, and the upper part of the new common channel (Fig. 2B).

### Postoperative management

After surgery, pain management is initiated. Patients begin ambulating few hours after the surgery. Twenty-four hours after the operation, we perform an upper gastrointestinal radiological contrast study with oral Gastrografin® with the patient standing up and lying on his left side to verify that the jejunum-jejunum anastomosis is not leaking. Once we have verified that there is no leaking, the drain is removed. Then the patient begin eating a clear liquid diet. The patient is discharged from the hospital 48 hr after surgery with oral tolerance. They drink liquid diet in the 1st week, semifluids in 2nd week, purée in 3-4th weeks and normal diet after one month of surgery. The patients were reviewed at 10 days, 1, 3, 6 and 12 months.

### Discussion

Morbid obesity is an epidemic disease for which, at present, bariatric surgery is the only effective treatment. Despite its success, some patients required reoperation due to failure of the surgery<sup>15</sup>.

According to Larsen et al<sup>16</sup>, failure in bariatric surgery for lack of weight loss, can produce a low quality of life and mental health affectation that may play a role in the decision for reoperation.

Even, the gold standard surgery Roux-en-Y gastric bypass (RYGB) to treat morbid obesity is one of the most failed procedure due to the large diffusion worldwide<sup>17</sup>. Rawlins et al<sup>18</sup> in their revision mentioned that weight loss failure after proximal Roux-en-Y gastric bypass occurs in  $\leq 35\%$  of cases.

However, the management of selected patients who fail to lose adequate weight or regain weight after primary bariatric surgery different to Roux-en-Y gastric bypass, can be repaired with RYGB<sup>19</sup>, but morbidity is three to fivefold higher than after primary RYGB<sup>20</sup>.

Bariatric surgery includes a large number of surgical procedures, some of which have become extinct and others continue performing. However, there is no clear procedure for the failure of a specific process, because reoperation is performed according to the characteristics of each patient and the experience of each surgeon.

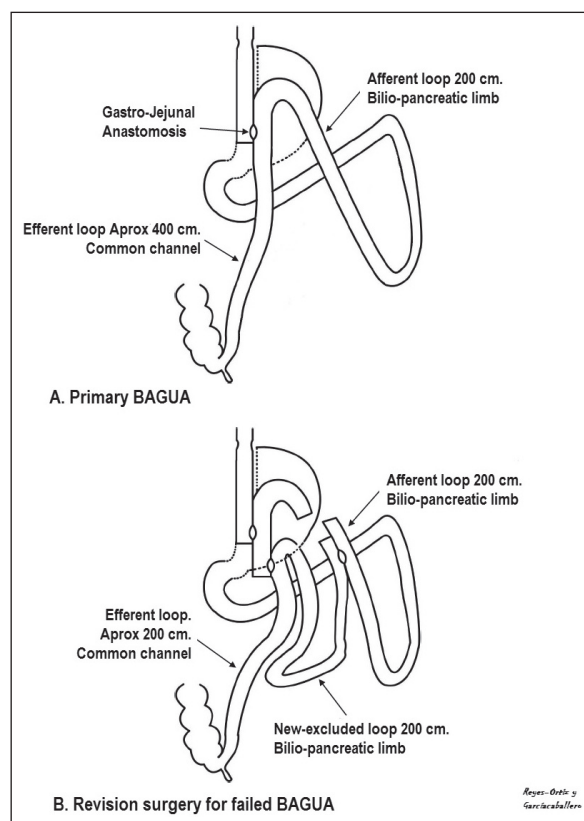


Fig. 2.—Surgical changes in the new technique for revision of failed BAGUA (B) compared with the primary surgery (A). As can be observed in (B), we cut the afferent loop before the primary gastro-jejunal anastomosis and the efferent loop around 20 cm below it. Then we restore the intestinal continuity anastomosing both stumps. Finally we performed a new jejuno-jejunal anastomosis for restoring the gastro-intestinal transit. The measures are in case of 6 m normal intestinal length.

Hence, in revision Bariatric surgery are some important debates to be resolved. First, those patients do not lose as much weight as primary surgery. Second, it could cause more complications, reoperations and use of ICU. Third, there are no established guidelines or procedures of revision surgery based on the evidence. Finally, there are factors that directly depend of the personal commitment and compliance of the patient that will be lifelong<sup>2,6</sup>.

The first consideration for the surgeon is the right choice of the primary surgery using criteria like that better weight loss and maintenance to prevent recurrence, and to be the easiest surgery to be revised if necessary. In our opinion, tailored BAGUA is the best choice for both losing and maintaining weight<sup>21</sup> or for revision surgery in case of insufficient weight loss or weight regain as well as excess weight loss.

Revision seems to be easy in Omega Loop GB (what we call BAGUA) when do not add an anti-reflux mechanism. However, when an anti-reflux mechanism is added, we put together the gastric pouch and the jejunum in approximately 12 cm, and to separate both structures is not so easy.

We found that separate the gastro-jejunal anastomosis is difficult. So that we have developed the procedure described in this paper, which allow us to review the tailored One Anastomosis Gastric Bypass (BAGUA), working always in healthy tissue not previously used as happened in primary surgery (Fig. 1A).

We add an anti-reflux mechanism to the Omega loop gastric bypass putting together the gastric pouch and the intestine in approximately 12 cm from the gastro-jejunostomy. This maneuver not only minimize the contact of the bilio-pancreatic secretion with the gastric mucosa and delay the gastric empty adding restriction, but also protect gastric pouch against dilatation as we have observed in some cases revised. That means that there is no necessity for reviewing gastric pouch as has been described by other authors after performing RYGB<sup>3,17</sup>. Hence, we need only to add more malabsorption because the restriction is maintained.

Therefore, we need to increase the length of the bilio-pancreatic limb and, consequently, shortens the common channel. Until now, always has been performed by separating the gastro-jejunal anastomosis with stapler which include a difficult dissection for separating the liver normally adhered to the anastomosis and the gastric pouch from the surrounding structures behind the anastomosis (of approximately 12 cm in our case).

The procedure we have developed consisting only in performing two latero-lateral jejunio-jejunal anastomoses using small intestine do not touched previously which is quick and safe. The whole procedure is carried out using only stapler (for the anastomosis and for closing the holes made for introducing the stapling device).

The aim of our rescue procedure was designed not only to achieve further weight reduction in patients

with unsuccessful weight loss after primary one anastomosis gastric bypass surgery, but also to treat complications such as excess weight lost. This is of paramount importance in patients with a BMI not healthy after primary surgery to whom require a rescue procedure since obesity-associated comorbidities are still present or concerns about excessive weight loss.

Our data support the idea that a failed surgical procedure, such as gastric bypass, should be corrected by another procedure purely malabsorptive procedure as the new technique mentioned in this paper. Nevertheless, to avoid the failure of the primary surgery, it is necessary to measure completely the length of the small intestine to exclude the correct length, as we do routinely after these experiences.

## Conclusions

A few number of patients with laparoscopic tailored One Anastomosis Gastric Bypass for morbid obesity will require a surgical rescue procedure due to excess or insufficient weight loss or weight regain.

We show how with only performing a double latero-lateral jejunio-jejunal anastomosis in healthy intestine not previously used, the patient can lose the necessary weight with a risk even lower than primary surgery, which is exceptional in revision surgery.

## References

1. Gloy VL, Briel M, Bhatt DL, Kashyap SR, Schauer PR, Mingrone G, Bucher HC, Nordmann AJ. Bariatric surgery versus non-surgical treatment for obesity: a systematic review and meta-analysis of randomised controlled trials. *BMJ* 2013 Oct 22;347:f5934.
2. Buhmann H, Vines L, Schiesser M. Operative strategies for patients with failed primary bariatric procedures. *Dig Surg* 2014;31:60-6
3. Patel S, Szomstein S, Rosenthal RJ. Reasons and outcomes of reoperative bariatric surgery for failed and complicated procedures (excluding adjustable gastric banding). *Obes Surg* 2011;21(8):1209-19.
4. Van Wageningen B, Berends FJ, Van Ramshorst B, Janssen IF. Revision of failed laparoscopic adjustable gastric banding to Roux-en-Y gastric bypass. *Obes Surg* 2006 Feb;16(2):137-41.
5. Odom J, Zalesin KC, Washington TL, Miller WW, Hakmeh B, Zaremba DL, Altattan M, Balasubramaniam M, Gibbs DS, Krause KR, Chengelis DL, Franklin BA, McCullough PA. Behavioral predictors of weight regain after bariatric surgery. *Obes Surg* 2010 Mar; 20(3):34.
6. de Gara CJ, Karmali S. The anatomy of a weight recidivism and revision bariatric surgical clinic. *Gastroenterol Res Pract* 2014; 2014:721095.
7. Stefanidis D, Malireddy K, Kuwada T, Phillips R, Zoog E, Gersin KS. Revisional bariatric surgery: perioperative morbidity is determined by type of procedure. *Surg Endosc* 2013;27:4504-10.
8. Hollowell PT, Stellato TA, Yao DA, Robinson A, Schuster MM, Graf KN. Should bariatric revisional surgery be avoided secondary to increased morbidity and mortality? *Am J Surg* 2009;197:391-6.
9. Brodin RE, Cody RP. Weight loss outcome of revisional bariatric operations varies according to the primary procedure. *Ann Surg* 2008;248:227-32.



10. Mohos E, Jánó Z, Richter D, Schmaldienst E, Sándor G, Mohos P, Horzov M, Tornai G, Prager M. Quality of Life, Weight Loss and Improvement of Co-morbidities After Primary and Revisional Laparoscopic Roux Y Gastric Bypass Procedure-Comparative Match Pair Study. *Obes Surg* 2014 Jun 10. [Epub ahead of print]
11. McKenna D, Selzer D, Burchett M, Choi J, Mattar SG. Revisional bariatric surgery is more effective for improving obesity-related co-morbidities than it is for reinducing major weight loss. *Surg Obes Relat Dis* 2013 Dec 18. pii: S1550-S1550-7289(13)00420-6. doi: 10.1016/j.soard.2013.12.007. [Epub ahead of print]
12. Stroh C, Weiner R, Wolff S, Knoll C, Manger T; Arbeitsgruppe Adipositas chirurgie, Kompetenznetz Adipositas. Revisional surgery and reoperations in obesity and metabolic surgery: Data analysis of the German bariatric surgery registry 2005-2012. *Chirurg* 2014 May 15. [Epub ahead of print]
13. Brethauer SA, Kothari S, Sudan R, Williams B, English WJ, Brengman M, Kurian M, Hutter M, Stegemann L, Kallies K, Nguyen NT, Ponce J, Morton JM. Systematic review on reoperative bariatric surgery: American Society for Metabolic and Bariatric Surgery Revision Task Force. *Surg Obes Relat Dis* 2014 Feb 22. pii: S1550-7289(14)00060-4.
14. Sauerland S, Angrisani L, Belachew M, Chevallier JM, Favretti F, Finer N, et al. Obesity surgery: evidence-based guidelines of the European Association for Endoscopic Surgery (EAES). *Surg Endosc* 2005;19:200-21.
15. Roller JE, Provost DA. Revision of failed gastric restrictive operations to Roux-en-Y gastric bypass: impact of multiple prior bariatric operations on outcome. *Obes Surg* 2006 Jul;16(7):865-9.
16. Larsen JK1, Zijlstra H, van Ramshort B, Geenen R. Conversion to gastric bypass in patients with unsuccessful weight loss after gastric banding may depend on mental quality of life. *Obes Facts* 2010;3(2):127-30.
17. Iannelli A, Schneck AS, Hébuterne X, Gugenheim J. Gastric pouch resizing for Roux-en-Y gastric bypass failure in patients with a dilated pouch. *Surg Obes Relat Dis* 2013;9:260-7.
18. Rawlins ML, Teel D 2nd, Hedgcorth K, Maguire JP. Revision of Roux-en-Y gastric bypass to distal bypass for failed weight loss. *Surg Obes Relat Dis* 2011;7:45-9.
19. Hamza N, Darwish A, Ammori MB, Abbas MH, Ammori BJ. Revision laparoscopic gastric bypass: an effective approach following failure of primary bariatric procedures. *Obes Surg* 2010;20:541-8.
20. Van Nieuwenhove Y, Ceelen W, Van Renterghem K, Van de Putte D, Henckens T, Pattyn P. Conversion from band to bypass in two steps reduces the risk for anastomotic strictures. *Obes Surg* 2011 Apr;21(4):501-5.
21. Lee WJ, Yu PJ, Wang W, Chen TC, Wei PL, Huang MT. Laparoscopic Roux-en-Y versus mini-gastric bypass for the treatment of morbid obesity: a prospective randomized controlled clinical trial. *Ann Surg* 2005;242:20-8.